

SHORT COMMUNICATIONS

Journal of Wildlife Diseases, 40(3), 2004, pp. 538–542
© Wildlife Disease Association 2004

West Nile Virus Infection in the Eastern Loggerhead Shrike (*Lanius ludovicianus migrans*): Pathology, Epidemiology, and Immunization

Mads F. Bertelsen,^{1,2,4,5} Rolf-Arne Ølberg,^{1,2} Graham J. Crawshaw,² Antonia Dibernardo,³ L. Robbin Lindsay,³ Michael Drebot,³ and Ian K. Barker¹ ¹ Department of Pathobiology, Ontario Veterinary College, University of Guelph, Guelph, Ontario N1G 2W1, Canada; ² Toronto Zoo, 361A Old Finch Road, Scarborough, Ontario M1B 5K7, Canada; ³ Zoonotic Diseases and Special Pathogens, National Microbiology Laboratory, Health Canada, 1015 Arlington Street, Winnipeg, Manitoba R3E 3R2, Canada; ⁴ Current address: Copenhagen Zoo, Søndre Fasanvej 79, DK-2000 Frederiksberg, Denmark; ⁵ Corresponding author (email: mfb@zoo.dk)

ABSTRACT: An outbreak of West Nile virus (WNV) infection occurred at a captive breeding facility for the endangered eastern loggerhead shrike (*Lanius ludovicianus migrans*) in August 2002. Within 10 d, five birds died; two were found dead, and the others died shortly after showing neurologic signs. West Nile virus was detected in all organs examined using immunohistochemistry, and its viral genome was amplified from brain and kidney samples using reverse transcription–polymerase chain reaction. None of the remaining birds in the colony had antibodies against WNV, which suggests a mortality rate of 100%. After vaccination with a commercial equine WNV vaccine 31 of 37 (84%) of the birds had WNV neutralizing antibodies.

Key words: Eastern loggerhead shrike, flaviviridae, immunization, immunohistochemistry, *Lanius ludovicianus migrans*, RT-PCR, West Nile virus.

The eastern loggerhead shrike (*Lanius ludovicianus migrans*) (ELS) is the migratory northern subspecies of the loggerhead shrike (*L. ludovicianus*) found throughout the United States. A severe population decline, starting in the 1950s, has reduced its range and numbers massively, and it is believed that there are only approximately 100 pairs remaining in the wild in North America. In 1997 and 1998, two captive populations were established in Canada, at the Avian Science and Conservation Center at McGill University, Montreal, Quebec, and at the Toronto Zoo, Toronto, Ontario. The first breeding occurred in 1998, and the total captive population in Canada is currently approximately 90 birds.

West Nile virus (WNV) is a flavivirus maintained in a mosquito-bird cycle. West

Nile virus was first found in North America in New York City in 1999 (Lanciotti et al., 1999), and it has since spread to most of the continent. Evidence of WNV was first found in Ontario in the summer of 2001 (Drebot et al., 2003). During 2002, WNV activity was documented in the Toronto area by mid-July (based on dead corvid surveillance), and the virus was first detected on the Toronto Zoo grounds on August 17 (Ølberg et al., 2004).

We here describe an outbreak of WNV in a captive group of ELS, including pathologic and serologic findings. Furthermore, we describe the effect of a vaccination program in the captive population.

In the summer of 2002, 43 birds were housed at the Toronto Zoo ELS breeding facility (43°49'28"N, 79°11'09"W). The majority of the birds had access to outdoor aviaries beginning in mid-April. From 29 August to 7 September, five shrikes were found dead or died shortly after showing clinical signs. Clinical signs were recorded, and supportive therapy was provided as needed. After the first two deaths, the remaining shrikes were confined to indoor quarters, to prevent exposure to mosquitoes.

Dead birds underwent a complete post-mortem examination, and tissues were collected for histopathology and virology. Representative samples of all major organs were collected in 10% buffered formalin, processed routinely for histopathology, sectioned at 6 µm, and stained with hematoxylin and eosin. A second set of slides

was prepared for immunohistochemistry at the Histopathology Section, Animal Health Laboratory, Laboratory Services Division, University of Guelph, Guelph, Ontario. In brief, tissue sections were deparaffinized and rehydrated, treated with 3% hydrogen peroxide to block endogenous tissue peroxidases, and subsequently treated with proteinase K (DAKO Cytomation, Inc., Mississauga, Ontario, Canada) for 12 min at 21 C. After a 15-min incubation with universal blocker (DAKO Cytomation), sections were incubated with rabbit polyclonal anti-WNV antiserum (Dr. Hana Weingartl, Canadian Food Inspection Agency, Winnipeg, Manitoba) diluted 1:400 for 30 min at 21 C. Goat anti-rabbit immunoglobulin conjugated to a horseradish peroxidase-labeled polymer (EnVision HRP; DAKO Cytomation) was used as the secondary antibody, with a 30-min incubation at 21 C. Nova Red (Vector Laboratories Canada Inc., Burlington, Ontario, Canada) was used as chromogen, and tissues were counterstained with Harris Hematoxylin (Fisher Scientific, Toronto, Ontario, Canada). For negative controls, non-immune rabbit serum was substituted for WNV antiserum.

Approximately 6 mm³ pieces of brain, kidney, and spleen were collected aseptically, pooled, and homogenized for 60 sec in a grinding solution (Medical Analysis Systems, Camarillo, California, USA). VecTestTM (Medical Analysis Systems), an antigen capture wicking assay for WNV, was subsequently used on these homogenates, according to the manufacturer's instructions.

Brain and kidney samples from all birds were collected aseptically and analyzed for the presence of WNV RNA by real-time TaqMan[®] reverse transcription-polymerase chain reaction (RT-PCR) assays, as described by Lanciotti et al. (2000). In brief, RNA was extracted from 150–200 µl of tissue homogenates using QIAamp viral RNA kits (Qiagen Inc., Mississauga, Ontario, Canada). A final volume of 70 µl of eluted RNA was stored at –80 C until

used. Five microliters of RNA was combined with the appropriate primers and probes in buffer using the TaqMan[®] RT-PCR ready-mix kit (PE Applied Biosystems, Foster City, California, USA). Samples were subjected to 40 amplification cycles in an ABI Prism 7700 Sequence Detection System instrument (PE Applied Biosystems), according to the manufacturer's protocol for TaqMan[®] RT-PCR cycling conditions. All tissue extracts were screened with a primer and probe set specific to the 3' non-translated region of the viral genome, and positive extracts were further tested by carrying out an additional TaqMan[®] RT-PCR using primers designed to amplify a portion of the ENV gene (Lanciotti et al., 2000). Tissues were considered to be positive only if positive results were obtained using both primer and probe sets.

In January 2003, the surviving birds were manually restrained, and 0.25 ml of blood was obtained from the right jugular vein and immediately placed in lithium-heparinized plasma separator tubes (Microtainer[®]; Becton Dickinson and Co., Franklin Lakes, New Jersey, USA). After collection, the plasma was separated by centrifugation and frozen. The birds were then vaccinated intramuscularly with 0.5 ml of an inactivated WNV vaccine (Fort Dodge Animal Health, Wyeth Pharmaceuticals, Markham, Ontario). The vaccine was given in two doses, half on either side of the pectoral muscle. Two boosters were given 3 and 6 wk later. A week after the second booster, blood was obtained again.

The plasma samples were analyzed for WNV neutralizing antibodies at the National Microbiology Laboratory (Winnipeg, Manitoba, Canada) using an in-house plaque-reduction neutralization test (PRNT), as described elsewhere (Weingartl et al., 2003). A known amount of virus (e.g., 100 plaque-forming units) was incubated for 90 min at 37 C with increasing dilutions of test sera. After this adsorption, 100 µl of the virus-serum mixture was added to a fully confluent Vero cell (C1008; ATCC, Ma-

nassas, Virginia, USA) monolayer (in six-well tissue-culture plates) and incubated for 1 hr at 37 C. After the infection, 3 ml of an agar overlay was applied to each well, and the plates were incubated at 37 C in 5% CO₂ for 72 hr. A second agar overlay that contained vital dye neutral red was added, and the presence or absence of plaques was noted after an additional 18 hr of incubation. By determining the final dilution of serum that led to a 90% reduction in plaque formation, an end-point titer for neutralization activity was calculated.

Clinical signs were observed in two of the five affected shrikes. One was found to be lethargic and recumbent on the bottom of its cage; it died when handled. Another shrike was also found on the bottom of its cage. It showed lethargy and posterior paresis. This bird was given supplemental nutrition and fluid therapy and was placed in a warm incubator supplemented with oxygen. It was found dead the next morning.

There were no obvious demographic trends in the affected birds. The age ranged from 2.5 mo to 5 yr, and three females and two males were affected.

Pronounced splenomegaly (5/5), marked pulmonary congestion (5/5), and variable congestion of the heart (4/5) and liver (3/5) were evident at the time of gross necropsy. Microscopic lesions included massive splenic coagulation necrosis with fibrin deposition (5/5) and pulmonary congestion (5/5), edema (4/5), and fibrin deposition (4/5). There was mild multifocal pancreatic necrosis (5/5), mild perivascular nonsuppurative hepatitis with scattered single-cell necrosis (5/5), moderate scattered intestinal crypt necrosis (3/5), nonsuppurative myocarditis (2/5), and mild nonsuppurative encephalitis (1/5). In two of the birds, severe fungal pneumonia caused by organisms morphologically consistent with an *Aspergillus* sp. was seen; this was interpreted as a terminal event on the basis of the minimal host reaction.

Immunohistochemistry demonstrated the presence of WNV antigen in all tissues

examined (Table 1). Spleen, intestine, and lung consistently had very high levels of antigen, as evidenced by widespread and intense staining, whereas lower levels were present in liver, kidney, proventriculus, heart, skin, and gonad. Little viral antigen was evident in ventriculus, pancreas, and brain.

In all cases, the VecTest assay was positive (clear color change of the wick) on tissue homogenates. All five birds tested positive for WNV RNA by RT-PCR.

Before vaccination, no antibody was detected by PRNT in the 37 birds tested. After vaccination, six birds (16%) had no detectable antibody, whereas 31 had an increased titer ranging from 20 to 2,560 (Fig. 1). The majority of birds (65%) had a titer between 40 and 320. In one bird, insufficient sample volume precluded the PRNT analysis.

The plasma samples were initially analyzed for WNV IgG antibodies using an indirect enzyme-linked immunosorbent assay (ELISA) that incorporated a horseradish peroxidase-conjugated goat anti-wild bird immunoglobulin (Ebel et al., 2002). The ELISA failed to detect WNV antibody-positive serum samples collected from vaccinated birds, presumably because of the inability of the goat anti-bird conjugate to recognize shrike immunoglobulin.

Multiple North American bird species appear to be sensitive to infection with WNV (Komar et al., 2003), but the outcome of infection varies. If it can be assumed that exposed birds will either die or produce neutralizing antibodies, the mortality rate in this outbreak was 100%, which indicates that the ELS is highly susceptible to WNV. Similar, very high mortality rates have been reported in experimentally infected corvids, as well as certain passerines and charadriiformes (Work et al., 1955; Hubálek and Halouzka, 1996; Komar et al., 2003). In contrast, little or no mortality has been reported in several other species (Komar et al., 2001, 2003).

In four of the five affected shrikes the

TABLE 1. Immunohistochemical demonstration of West Nile virus antigen in organs from five eastern loggerhead shrikes. Case numbers reflect the order in which the birds died. The concentrations of viral antigen were scored on a subjective scale from no antigen to massively distributed staining.

Case no.	Immunohistochemical staining for West Nile virus												
	Spleen	Liver	Kidney	Proventriculus	Ventriculus	Intestine	Pancreas	Lung	Brain	Heart	Skin	Gonad	
1	++++ ^a	+	++	+++	++	+++	+	++	+	+	++	+++	
2	+++	+	+	+	+	+	++	++	+	+	+	+	
3	+++	+++	++	+	+	+++	+	+++	+	++	++	NE	
4	+++	+++	++	+++	+	+++	+	++	++	+++	+++	NE	
5	+	+	+	- ^b	-	+	+	-	+	+	+	-	

^a + to ++++ reflects subjective evaluation of concentration of viral antigen detected.

^b - = no antigen detected; NE = not examined.

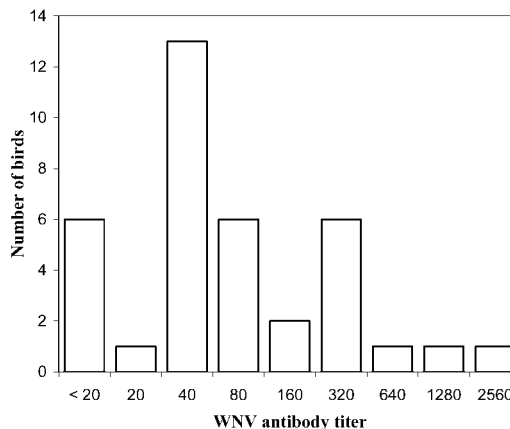


FIGURE 1. Distribution of West Nile virus (WNV) plaque-reduction neutralization test antibody titers in eastern loggerhead shrikes after vaccination with a commercial equine WNV vaccine (n=37).

lesions were extremely acute, characterized by necrosis and minimal mononuclear infiltration, and high levels of viral antigen were present even if no overt necrosis of infected cells was evident. Essentially all organs were infected, as has been described in a variety of species (Steele et al., 2000; Komar et al., 2003).

After the death of the first two birds on 29 August, all remaining birds were moved indoors, where they were housed individually, on 30 August. Hence, for the three last birds to die, the period from infection to death must have been at least 1, 3, and 8 days, respectively. This corresponds to findings by Komar et al. (2003) in other species experimentally infected with WNV. The relatively protracted course of the disease in the fifth bird corresponds well with the more chronic nature of lesions observed in this individual, including moderate nonsuppurative myocarditis and mild nonsuppurative encephalitis; these reactions were not evident in the first four birds to die. Furthermore, the immunohistochemical staining result was markedly lower in this bird (Table 1).

The very high concentration of virus in the gastrointestinal and urinary tracts and the lung, as demonstrated by immunohistochemistry, suggests that virus is likely

shed in excreta and oropharyngeal fluids in the ELS, as has been demonstrated in multiple other species (Komar et al., 2003). Contact transmission of WNV has been reported in several bird species maintained under laboratory conditions (McLean et al., 2002; Komar et al., 2003) and may occur when ELS are housed together. Furthermore, as a carnivore, the ELS may be susceptible to WNV infection if it consumes infected prey (Komar et al., 2003).

After vaccination, WNV neutralizing antibodies were demonstrated in 84% of the birds, which suggests that vaccination may protect ELS against WNV infection. The protective antibody level is largely unknown, but, in experimentally infected rock doves (*Columba livia*), titers ranged from 10 to 640, 2–9 wk after inoculation (Komar et al., 2003). Because ELS appears to be exquisitely susceptible to WNV, vaccination may be an important tool in the preservation of the species, at least in captivity.

We thank the staff at the Toronto Zoo for handling of and care for the shrikes, and the Histopathology Section, Animal Health Laboratory, Laboratory Services Division, University of Guelph, Guelph, Ontario, for carrying out the immunohistochemistry.

LITERATURE CITED

- DREBOT, M., R. LINDSAY, I. K. BARKER, P. A. BUCK, M. FEARON, F. HUNTER, P. SOCKETT, AND H. ARTSOB. 2003. West Nile virus surveillance and diagnostics: A Canadian perspective. *Canadian Journal of Infectious Diseases* 14: 105–114.
- EBEL, G. D., A. P. DUPUIS, D. NICHOLAS, D. YOUNG, J. MAFFEI, AND L. D. KRAMER. 2002. Detection by enzyme-linked immunosorbent assay of antibodies to West Nile virus in birds. *Emerging Infectious Diseases* 8: 979–982.
- HUBÁLEK, Z., AND J. HALOUZKA. 1996. Arthropod-borne viruses of vertebrates in Europe. *Acta Scientiarum Naturalium Brno* 30: 1–95.
- KOMAR, N., N. A. PANELLA, J. E. BURNS, S. W. DUSZA, T. M. MASCARENHAS, AND T. O. TALBOT. 2001. Serologic evidence for West Nile virus infection in birds in the New York City vicinity during an outbreak in 1999. *Emerging Infectious Diseases* 7: 621–625.
- , S. LANGEVIN, S. HINTEN, N. NEMETH, E. EDWARDS, D. HETTLER, B. DAVIS, R. BOWEN, AND M. BUNNING. 2003. Experimental infection of North American birds with the New York 1999 strain of West Nile virus. *Emerging Infectious Diseases* 9: 311–322.
- LANCIOTTI, R. S., J. T. ROEHRIG, V. DEUBEL, J. SMITH, M. PARKER, K. STEELE, B. CRISE, K. E. VOLPE, M. B. CRABTREE, J. H. SCHERRET, R. A. HALL, J. S. MACKENZIE, C. B. CROPP, B. PANIGRAHY, E. OSTLUND, B. SCHMITT, M. MALKINSON, C. BANET, J. WEISSMAN, N. KOMAR, H. M. SAVAGE, W. STONE, T. S. MCNAMARA, AND D. J. GUBLER. 1999. Origin of the West Nile virus responsible for an outbreak of encephalitis in the northeastern United States. *Science* 286: 2333–2337.
- , A. KERST, R. NASCI, M. GODSEY, C. MITCHELL, H. SAVAGE, N. KOMAR, N. PANELLA, AND B. ALLEN. 2000. Rapid detection of West Nile virus from human clinical specimens, field collected mosquitoes and avian samples by a TaqMan[®]RT-PCR assay. *Journal of Clinical Microbiology* 38: 4066–4071.
- MCLEAN, R. G., S. R. UBICO, D. BOURNE, AND N. KOMAR. 2002. West Nile virus in livestock and wildlife. *Current Topics in Microbiology and Immunology* 267: 271–308.
- ØLBERG, R. A., I. K. BARKER, G. C. CRAWSHAW, M. F. BERTELSEN, M. A. DREBOT, AND M. ANDONOVA. 2004. West Nile encephalitis in a Barbary macaque (*Macaca sylvanus*). *Emerging Infectious Diseases* 10: 712–714.
- STEELE, K. E., M. J. LINN, R. J. SCHOEPP, N. KOMAR, T. W. GEISBERT, R. M. MANDUCA, P. P. CALLE, B. L. RAPHAEL, T. L. CLIPPINGER, T. LARSEN, J. SMITH, R. S. LANCIOTTI, N. A. PANELLA, AND T. S. MCNAMARA. 2000. Pathology of fatal West Nile virus infections in native and exotic birds during the 1999 outbreak in New York City, New York. *Veterinary Pathology* 37: 208–224.
- WEINGARTL, H. M., M. A. DREBOT, Z. HUBALEK, J. HALOUZKA, M. ANDONOVA, A. DIBERNARDO, C. COTTAM-BIRT, J. LARENCE, AND P. MARSZAL. 2003. Comparison of assays for the detection of West Nile virus antibodies in chicken serum. *Canadian Journal of Veterinary Research* 67: 128–132.
- WORK, T., H. HURLBUT, AND R. TAYLOR. 1955. Indigenous wild birds of the Nile Delta as potential West Nile circulating reservoirs. *American Journal of Tropical Medicine and Hygiene* 4: 872–888.

Received for publication 3 December 2003.